Tratamento das Dissecções da Aorta Descendente Utilizando *Stents* Aórticos Introduzidos pela Artéria Femoral

José Honório de A. Palma da Fonseca

Outubro de 1999



Dotter et al 1969

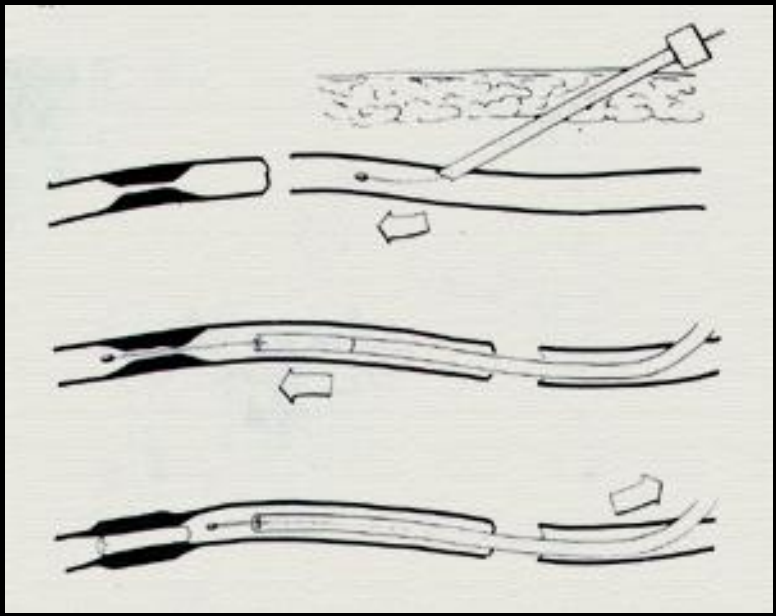

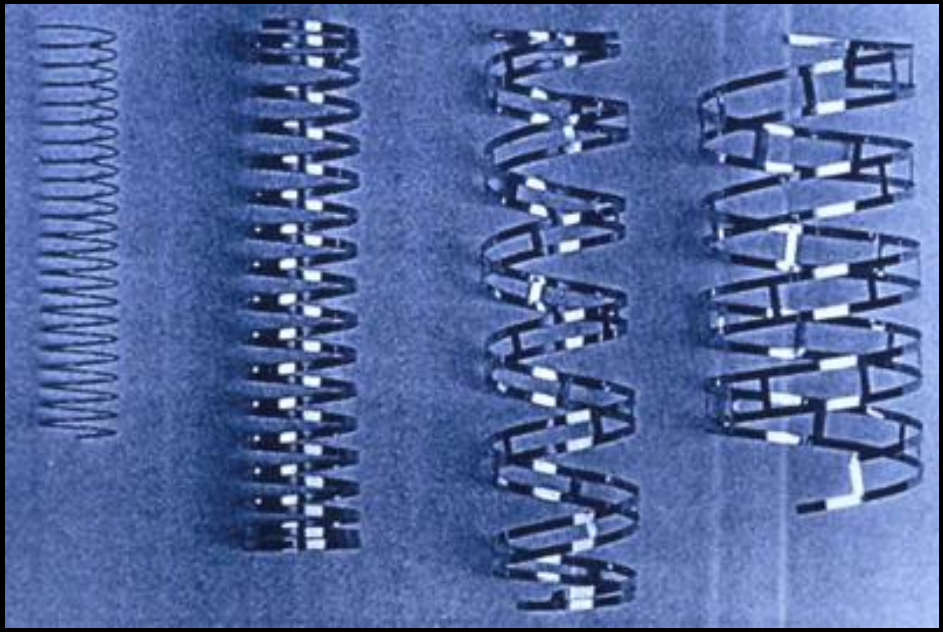

Parodi et al 1991

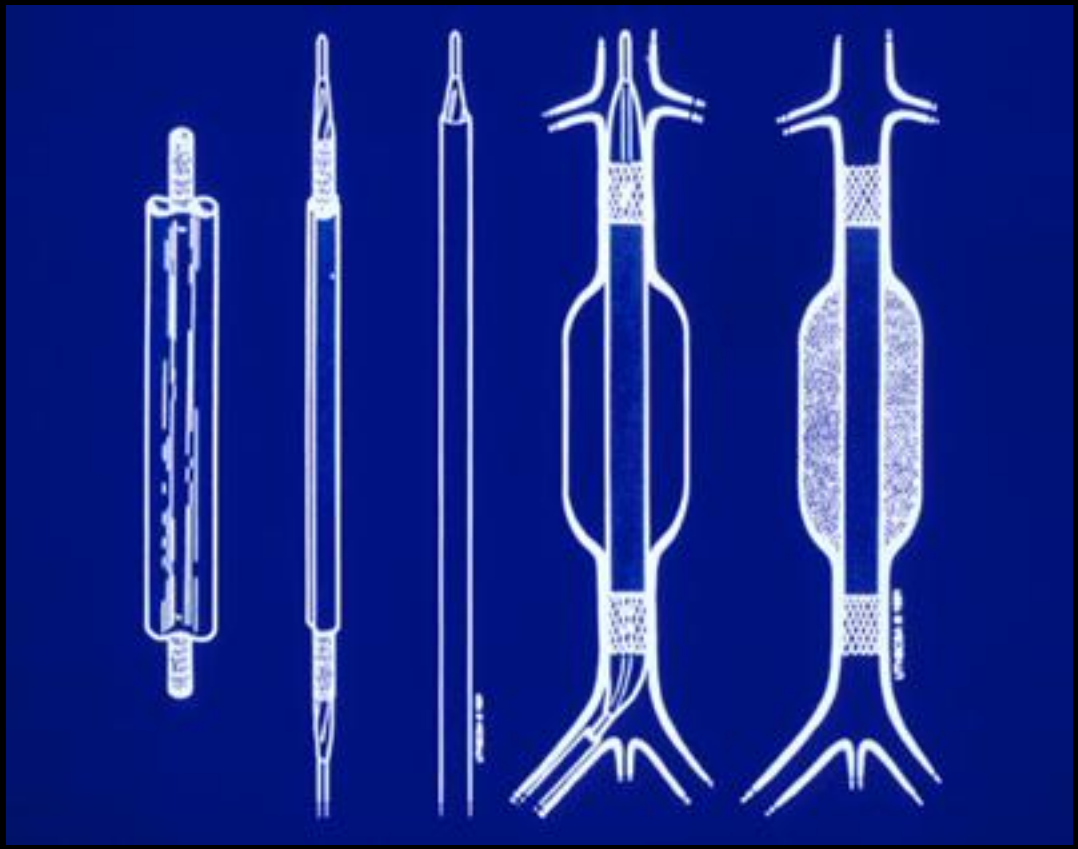

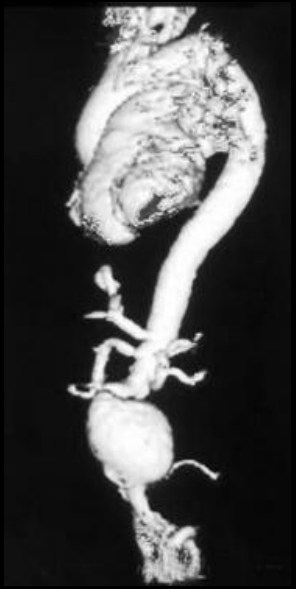

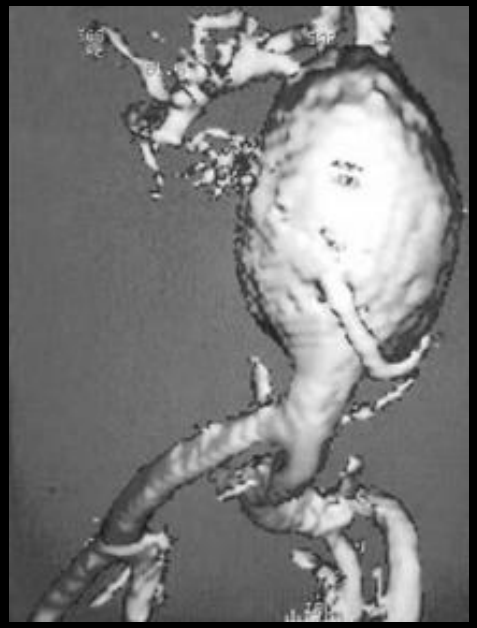

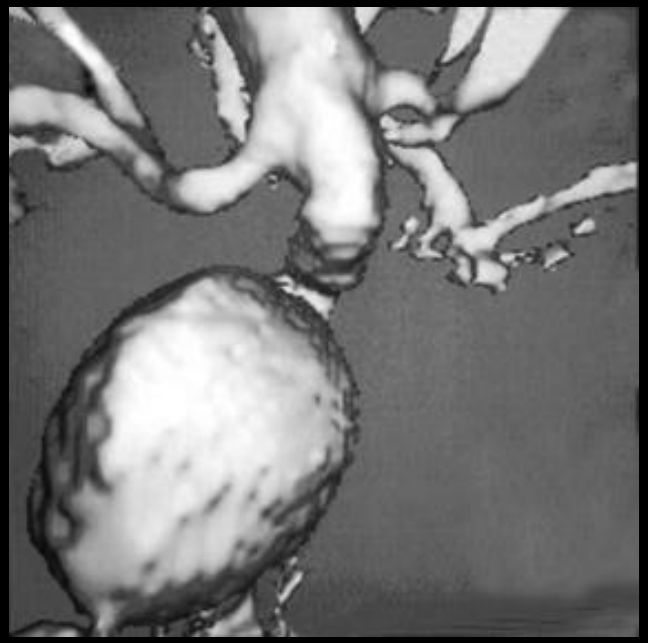

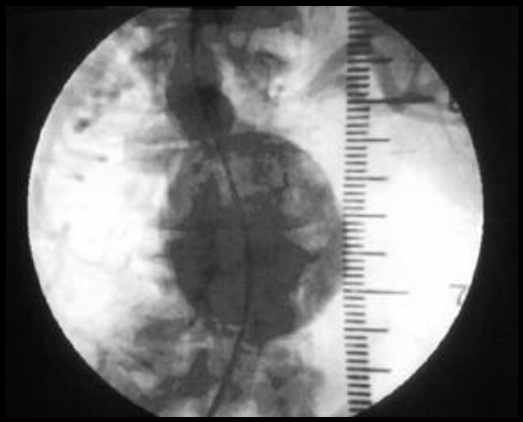

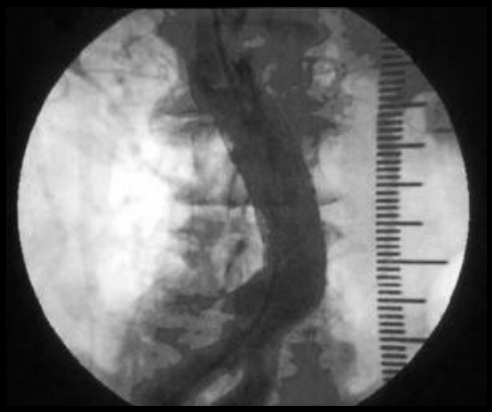

Dake et al 1994

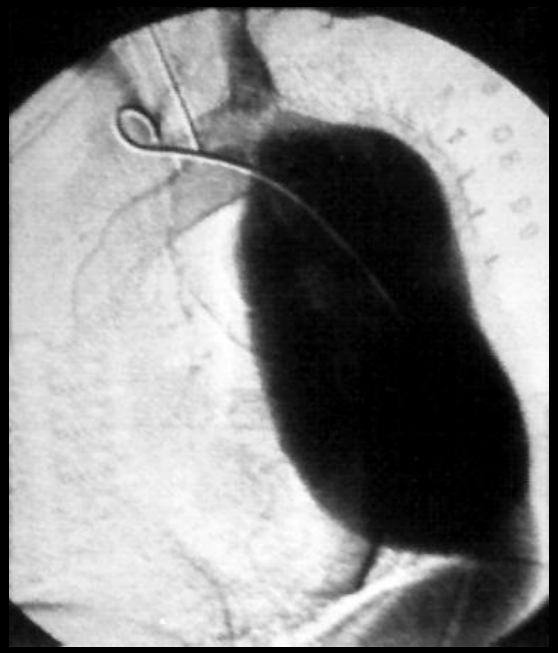

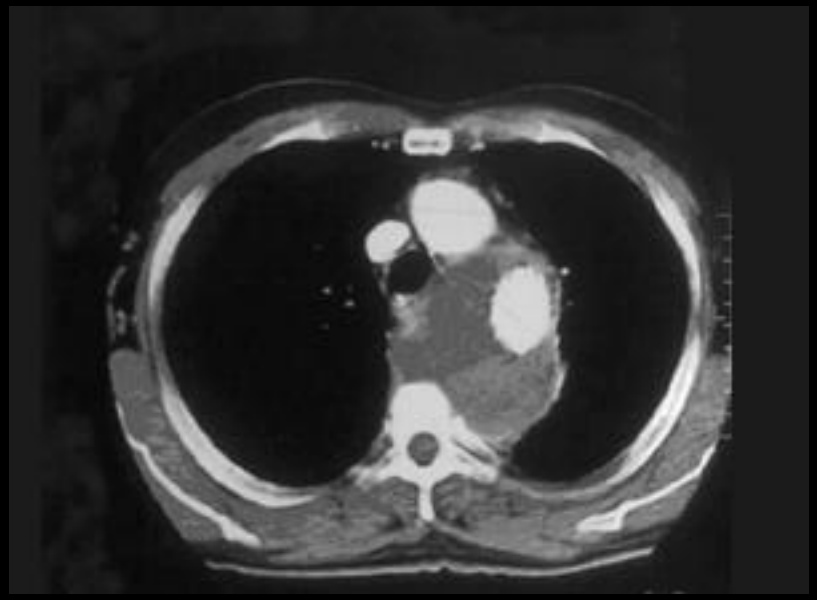

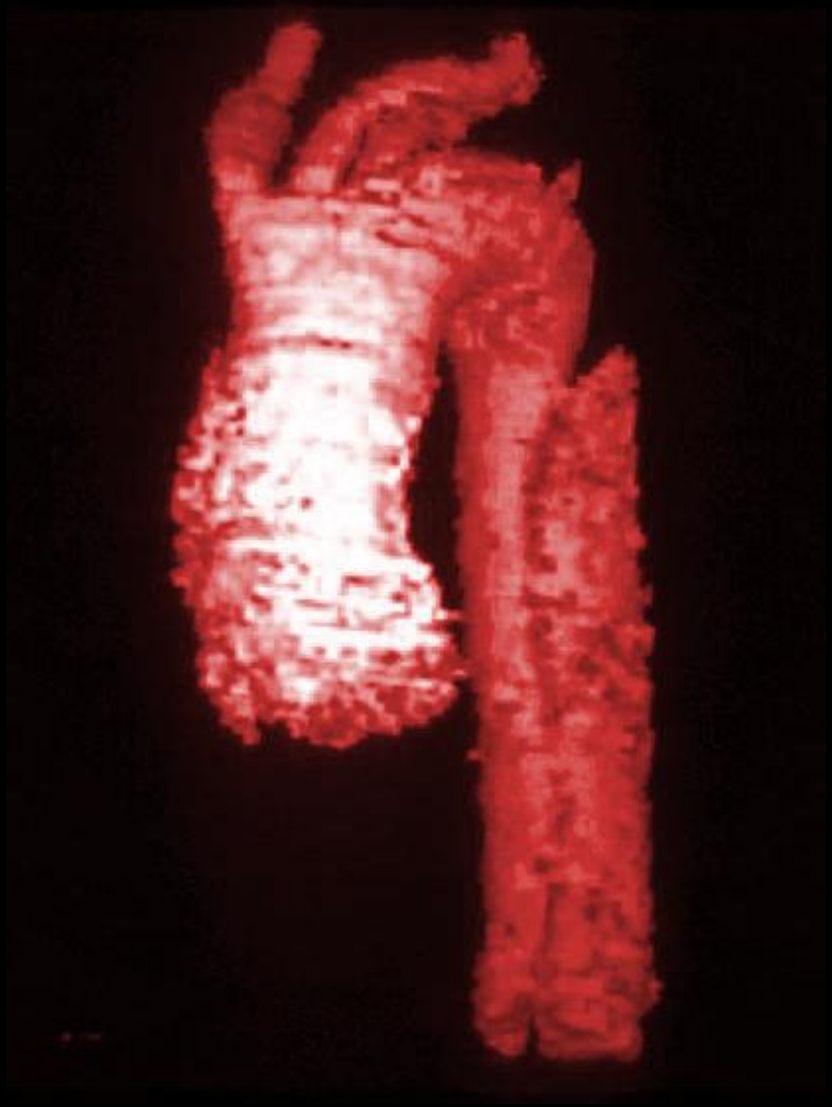

Surgical Treatment of Acute Type B Aortic Dissection Using an Endoprosthesis (Elephant Trunk)

J. Honório Palma, MD, Dirceu R. Almeida, MD, Antonio C. Carvalho, MD, José Carlos S. Andrade, MD, and Enio Buffolo, MD

Divisions of Cardiovascular Surgery and Cardiology, Escola Paulista de Medicina, São Paulo, Brazil

Background. The surgical treatment of acute complicated type B aortic dissection continues to be a challenge and is still associated with high morbidity and mortality rates.

Methods. Seventy consecutive patients with an acute type B aortic dissection underwent an elephant trunk procedure through a median sternotomy during deep hypothermic circulatory arrest. An endoprosthesis that was 22 to 24 mm in diameter was inserted through an incision in the arch and held in place with only proximal sutures.

Results. The mean arrest time was 31.4 ± 8.7 minutes, and it was possible to adequately position the endoluminal graft in every patient. The procedure was done in association with other procedures in 13 patients. There were six in-hospital deaths not related to the endoprosthesis, and four late deaths. Late reoperation was necessary in 6 patients to manage leakage at the proximal suture line.

Conclusions. The insertion of an endoprosthesis through the arch for the management of a complicated acute type B dissection has several advantages over the conventional thoracotomy approach. The hospital mortality rate in this series of 70 patients was 20%, and the actuarial 5-year survival rate was 62.5%. We consider the elephant trunk procedure the treatment of choice in patients with type B acute dissections, regardless of whether the dissection is complicated or not.

(Ann Thorac Surg 1997;63:1081–4)
© 1997 by The Society of Thoracic Surgeons

H. Borst 1983

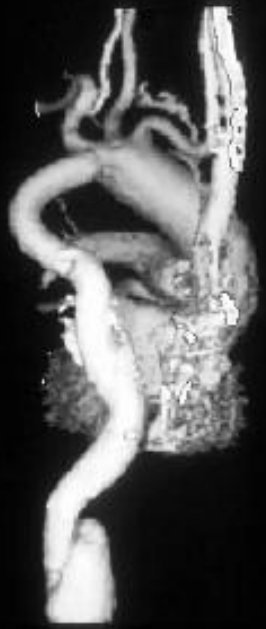

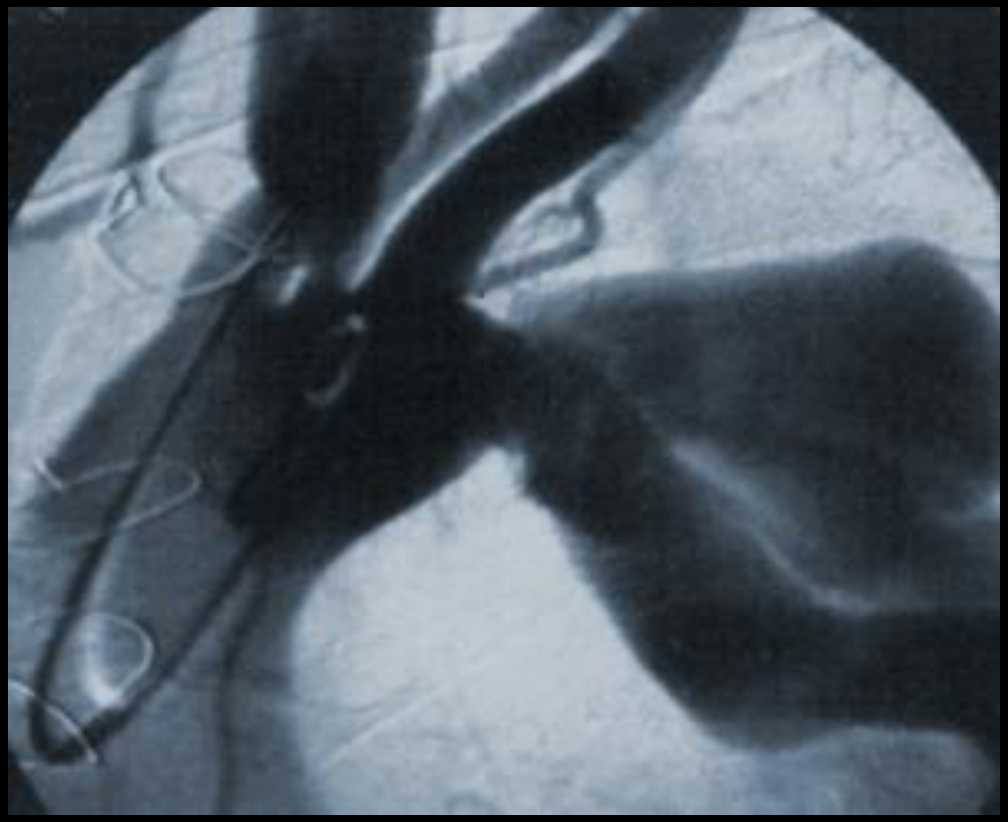



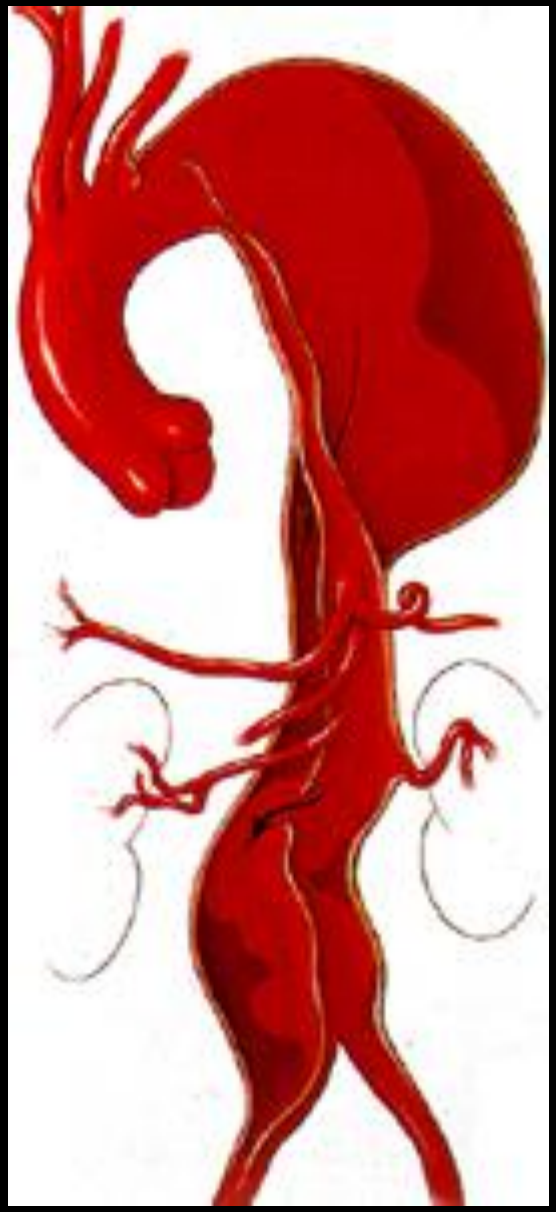

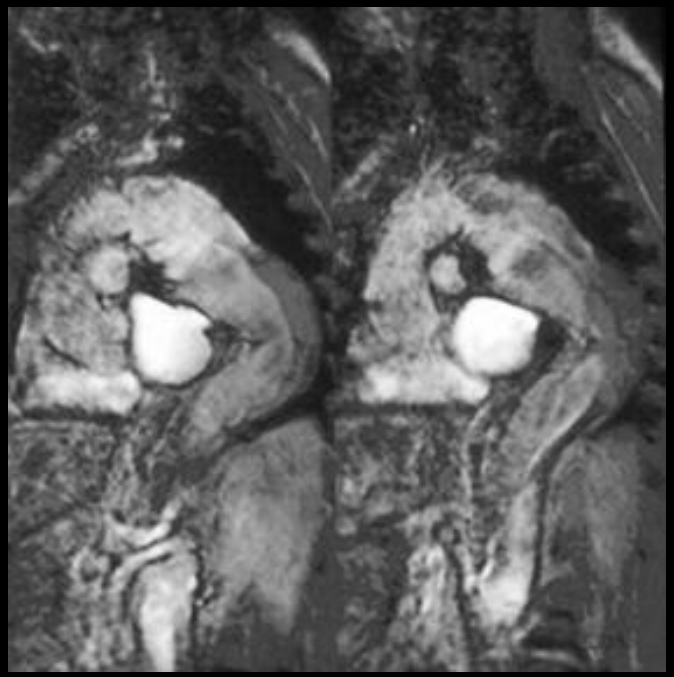

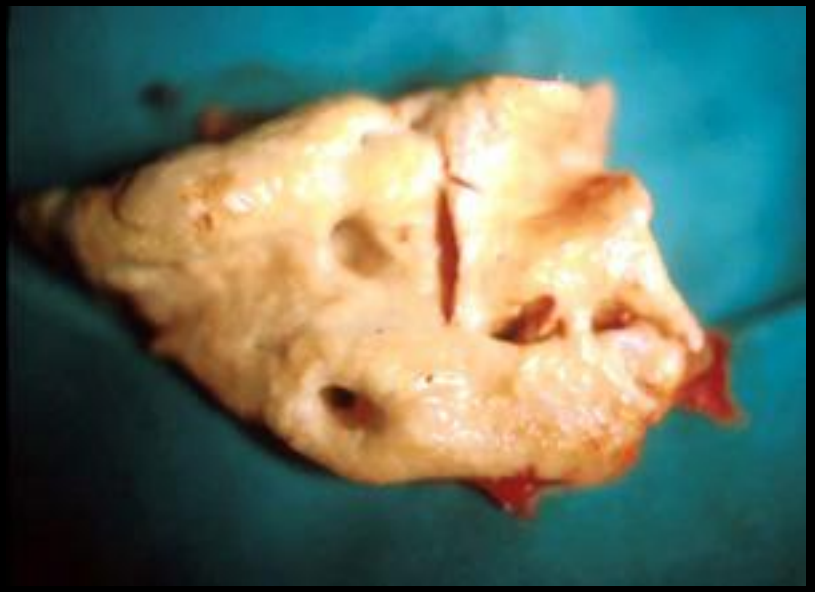

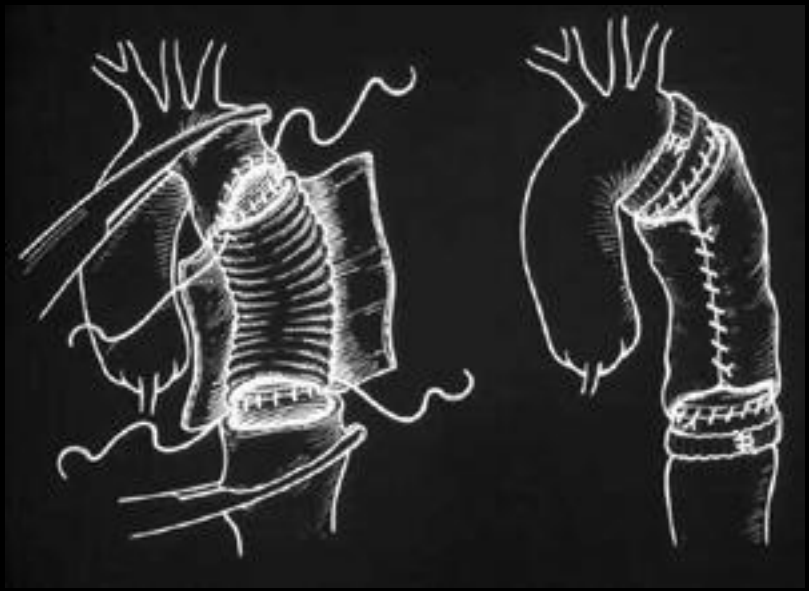

Nikolaus Geisthovel

Nikolaus Geisthovel



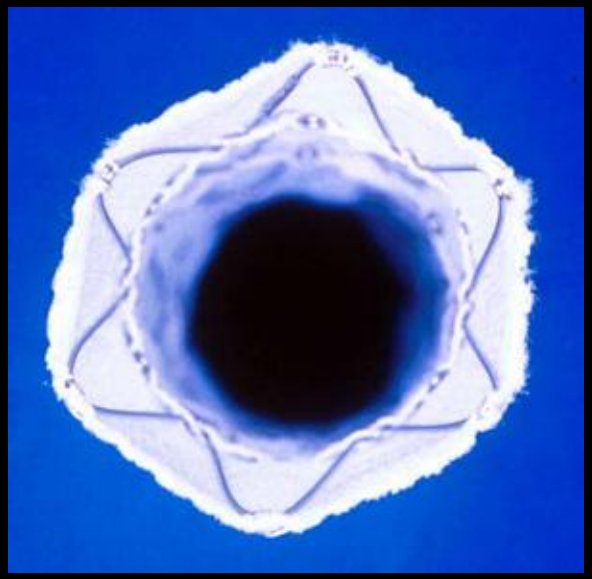





0
1
2
3
4

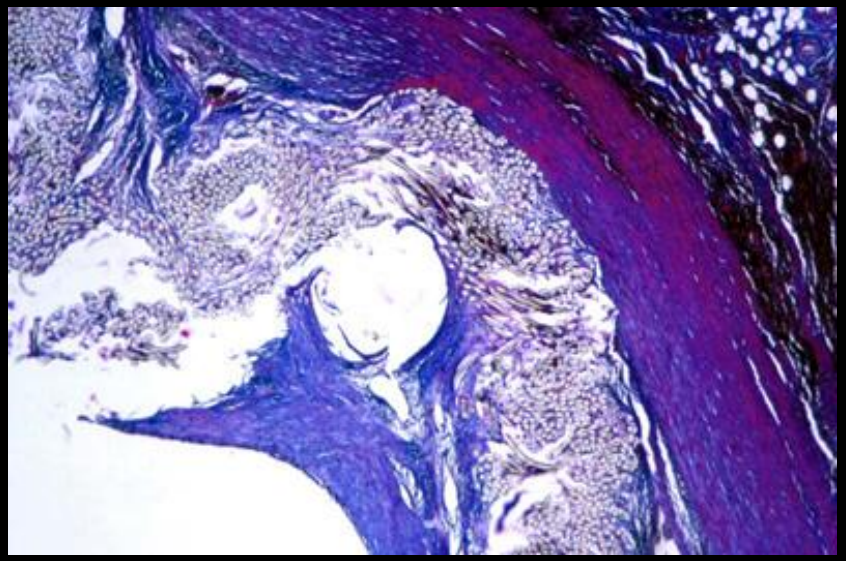

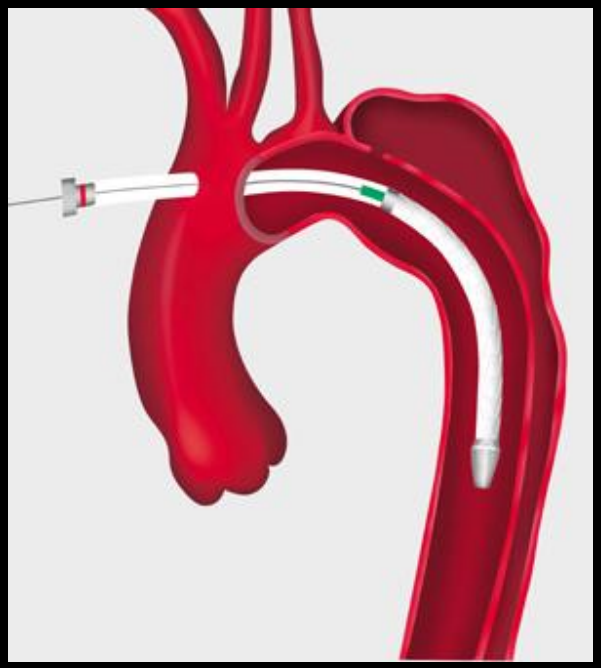

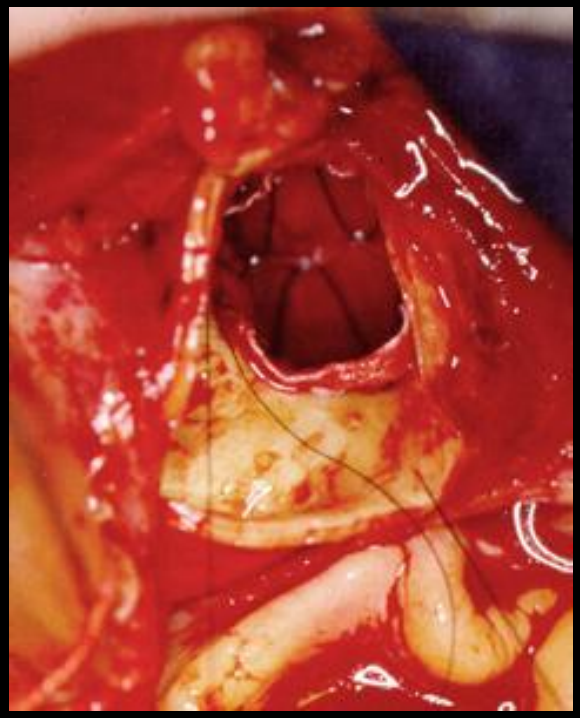

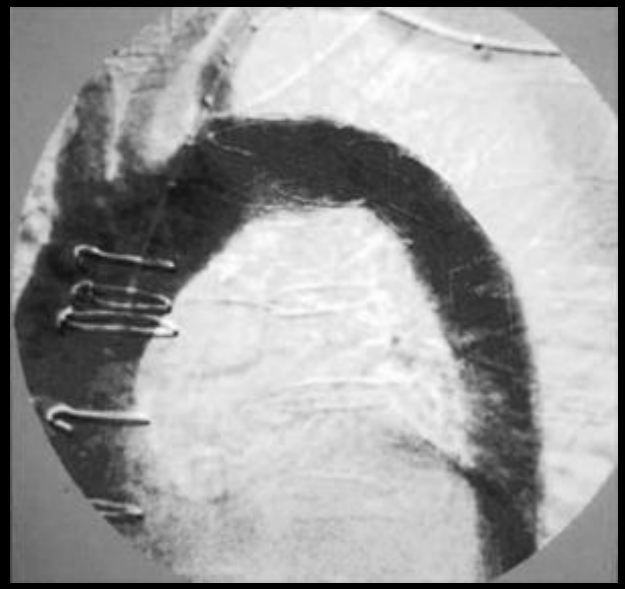

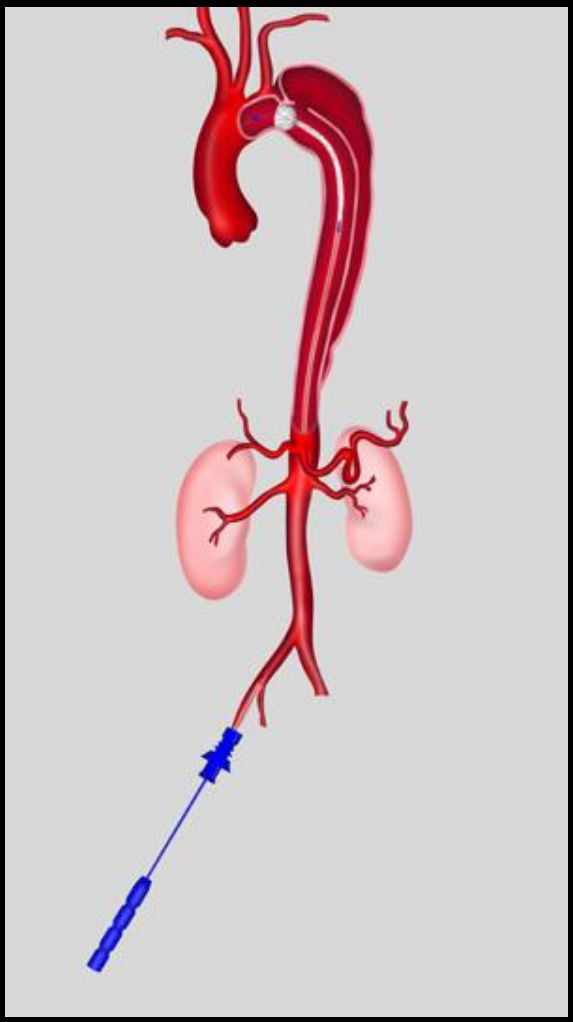

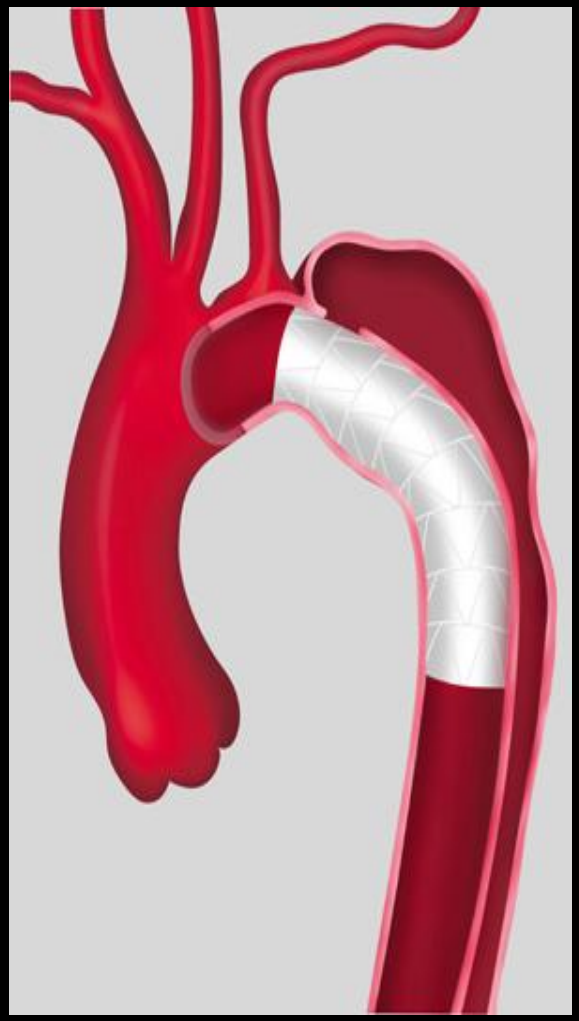

- 27 Pacientes
  - 77,8% - masculino
  - 22,2% - feminino

Hematoma Mural
3,7%

Úlcera de Aorta
11,1%

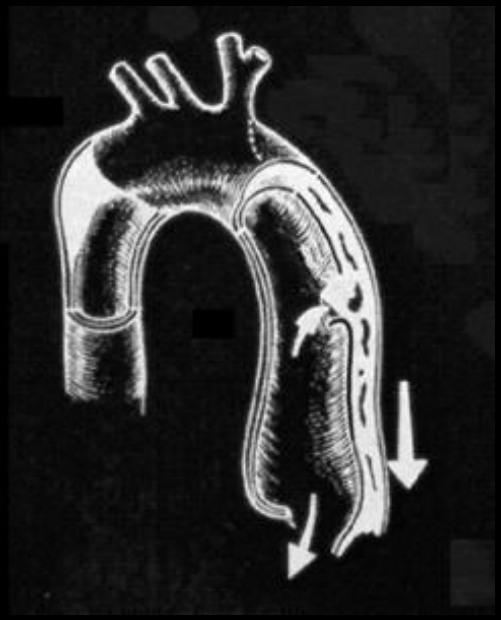

Dissecção Tipo B
85,2%

- Idade - 33 a 77 anos
- Média - 61,8
- Desvio Padrão - 10,5

Junho/96

Maio/99

- Tp de observação - 32 meses

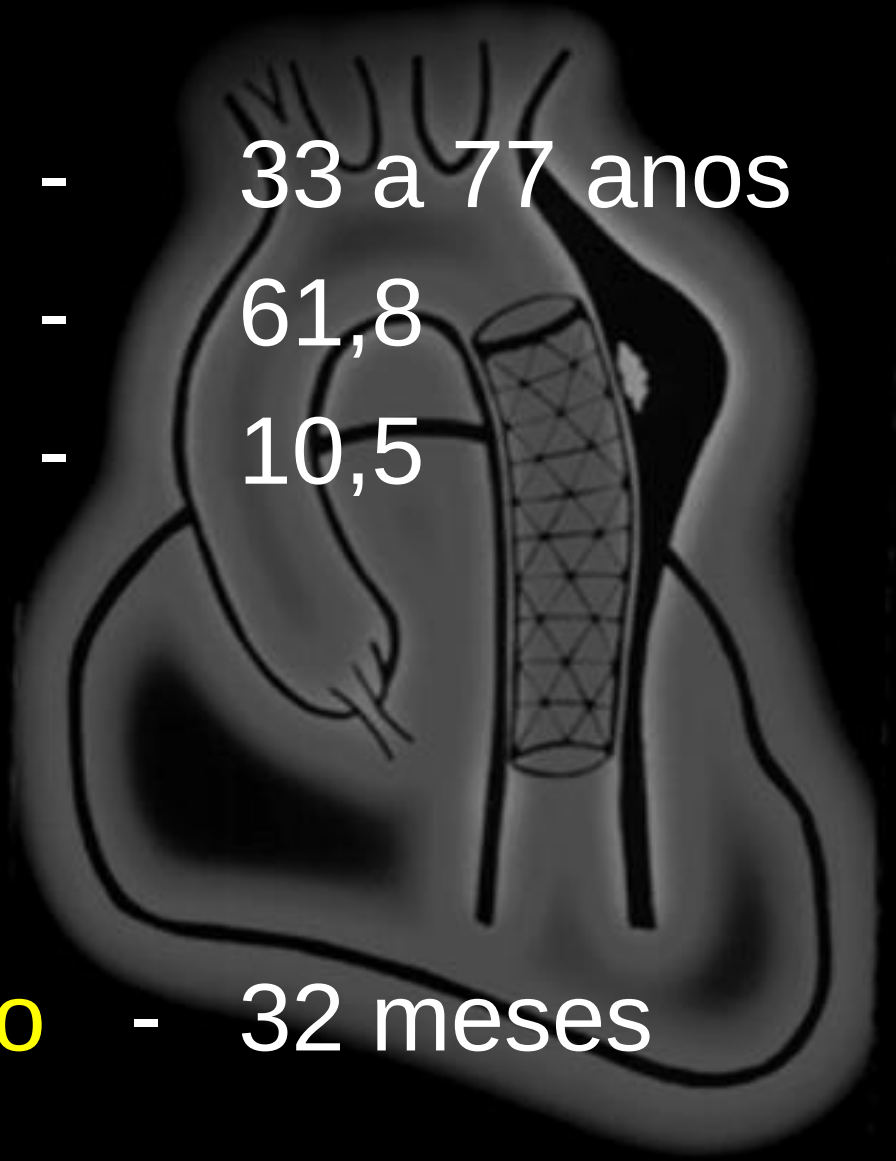

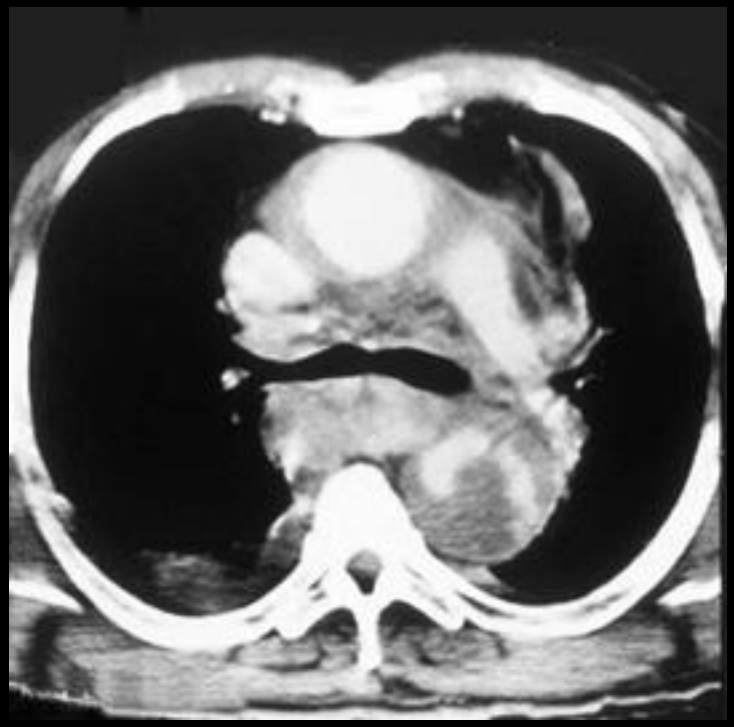

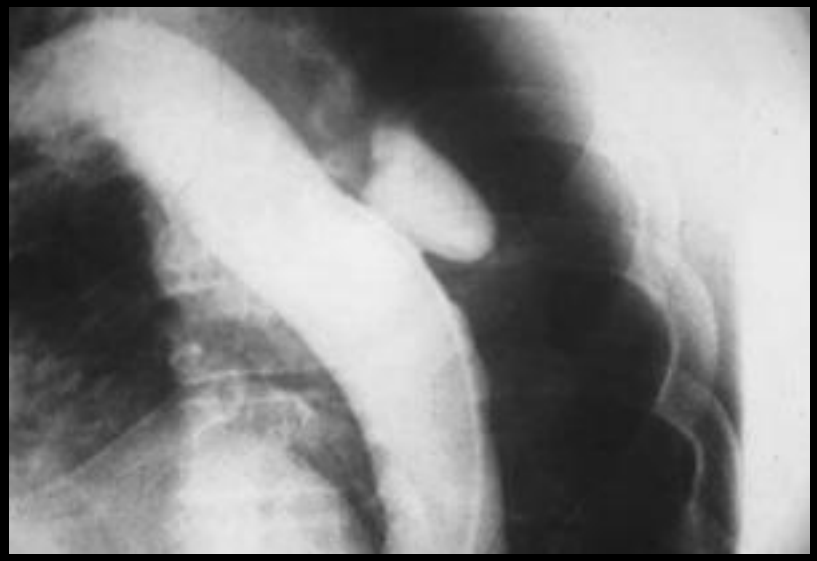

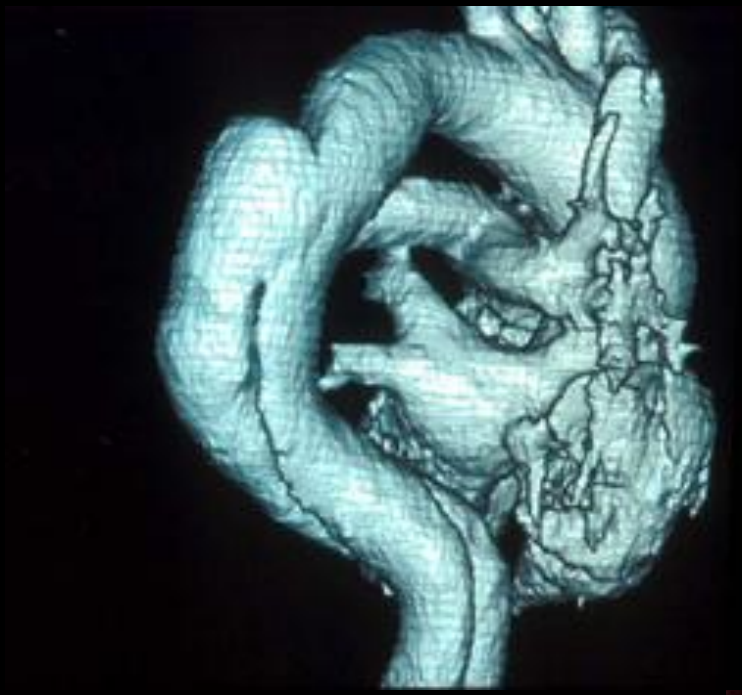

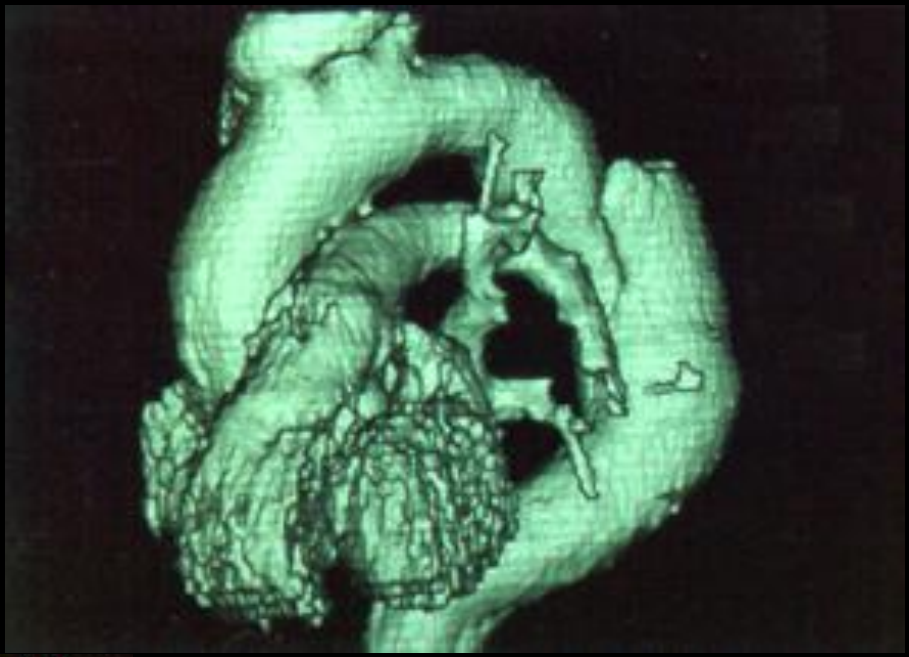

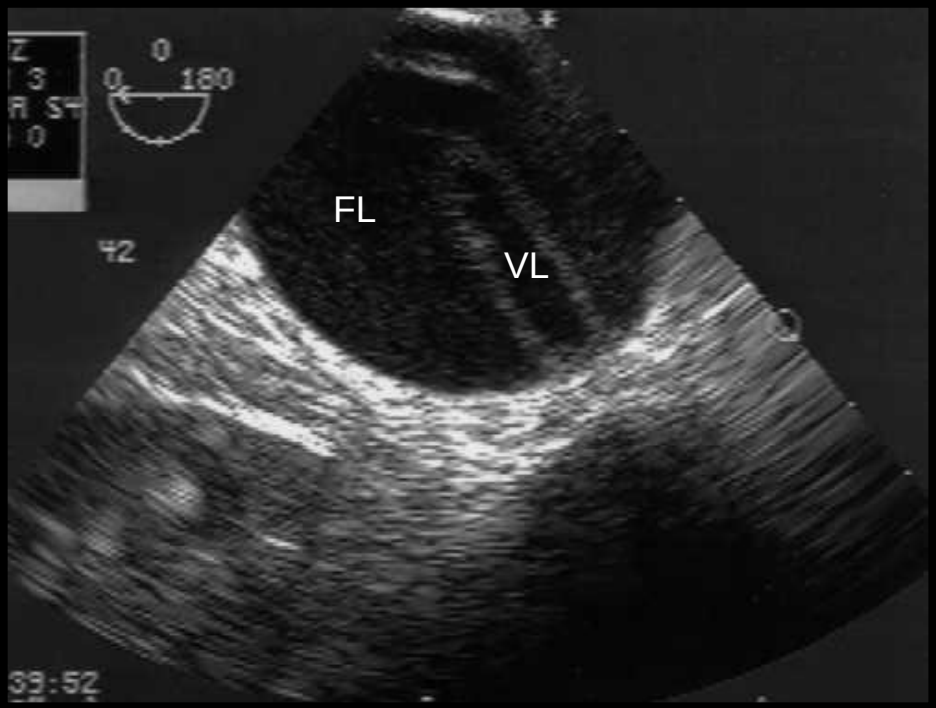
FL
VL

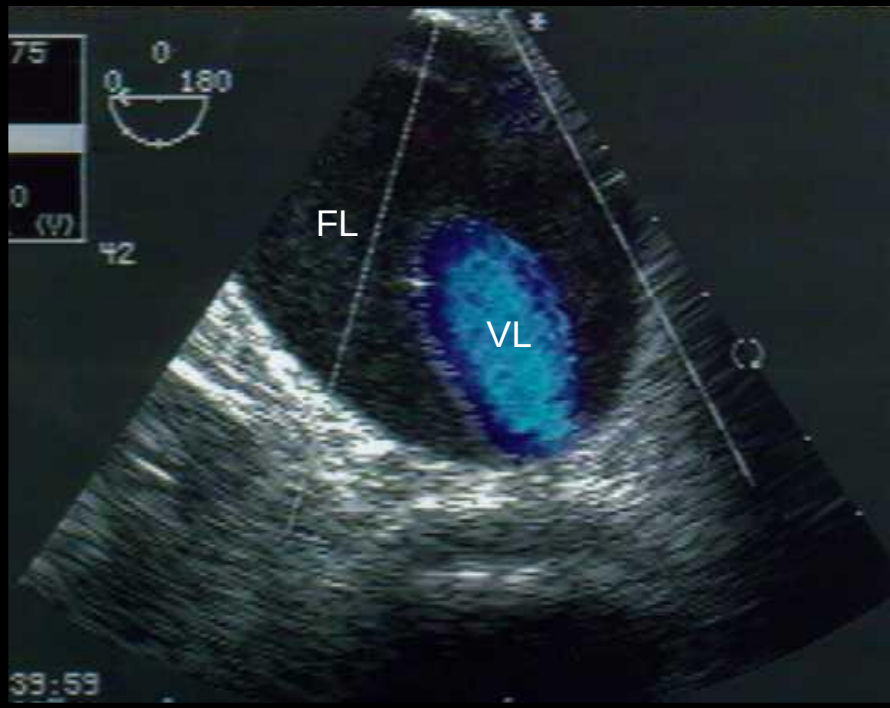
FL
VL

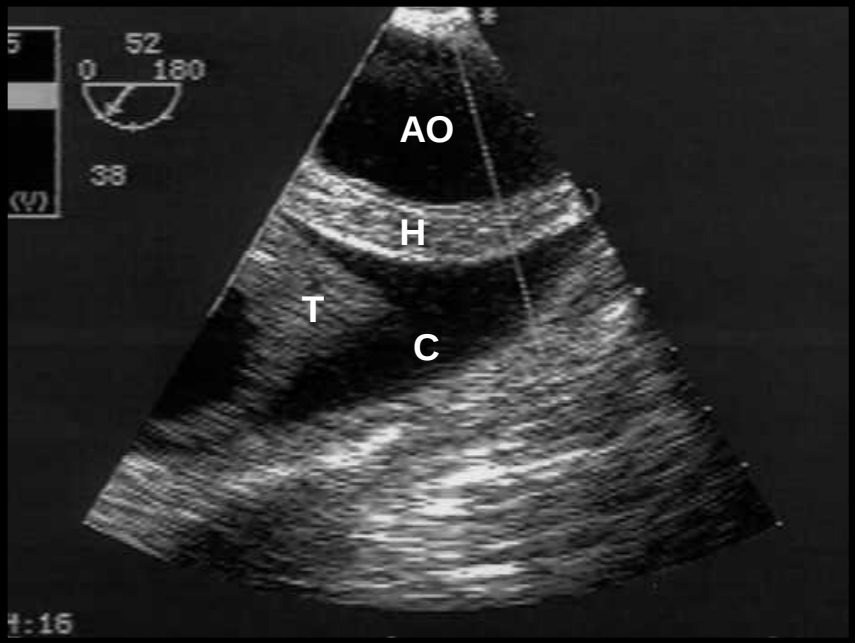
52
0
180
38
AO
H
T
C

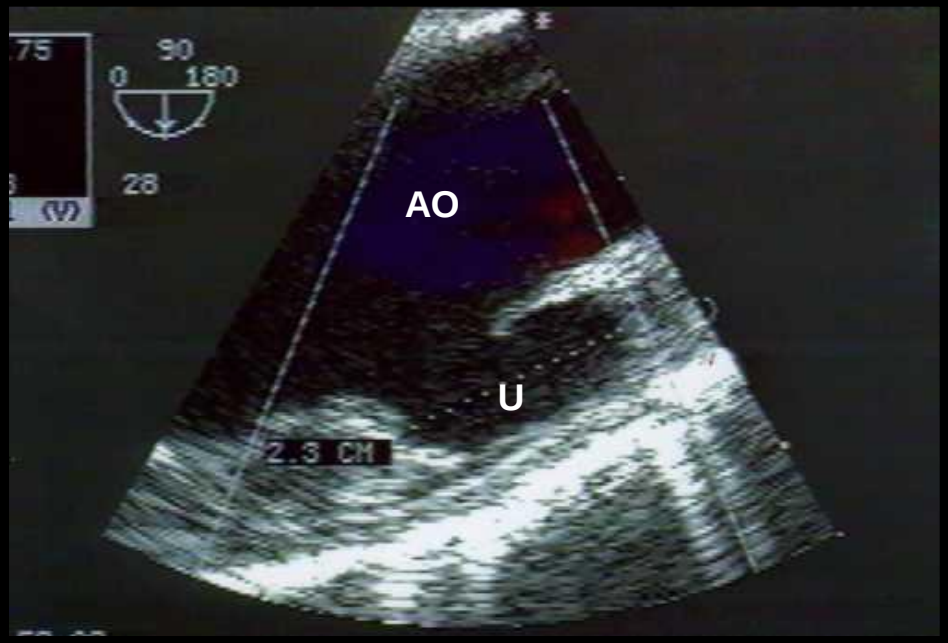
90
0
180
28
AO
U
2.3 CM

Complicações pré-operatórias

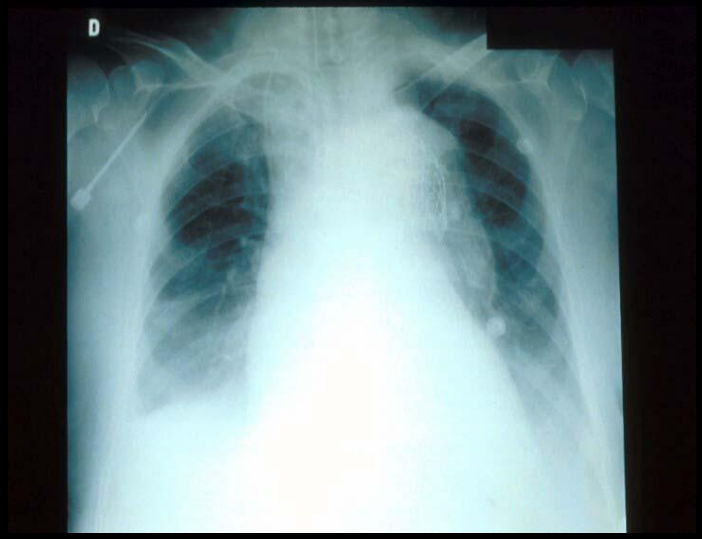

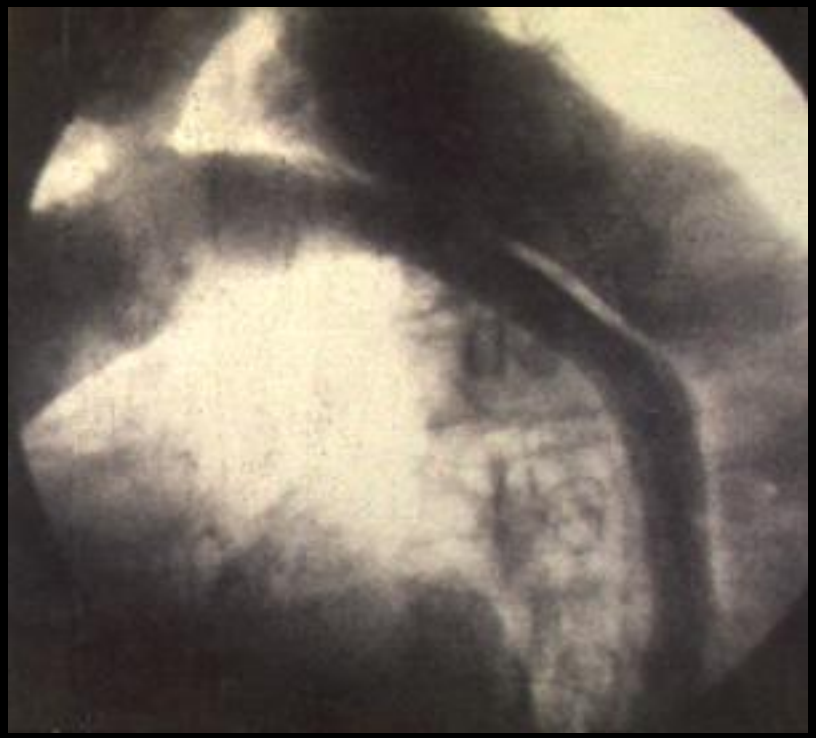

- Dor intratável
- Isquemia M. I.
- Derrame pleural
- Hemoptise
- Expansão

Via de acesso

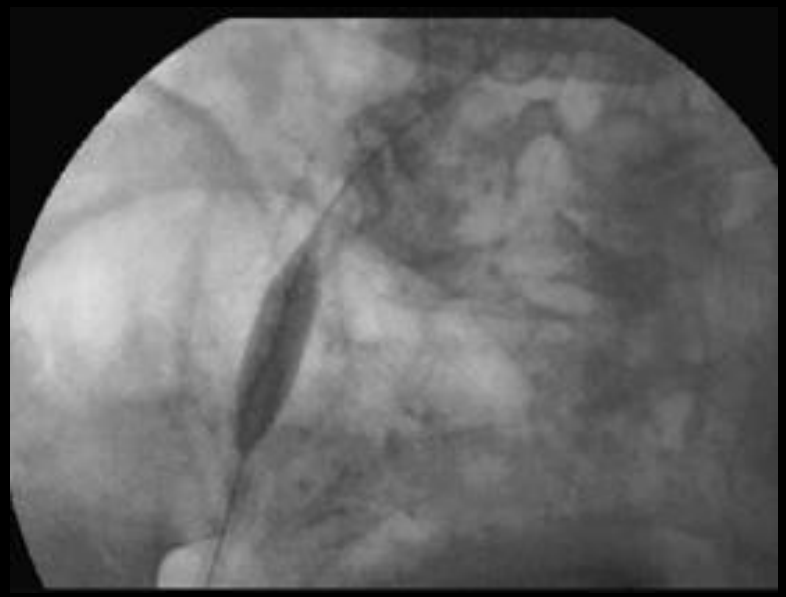

Artéria femoral D. 81,5%

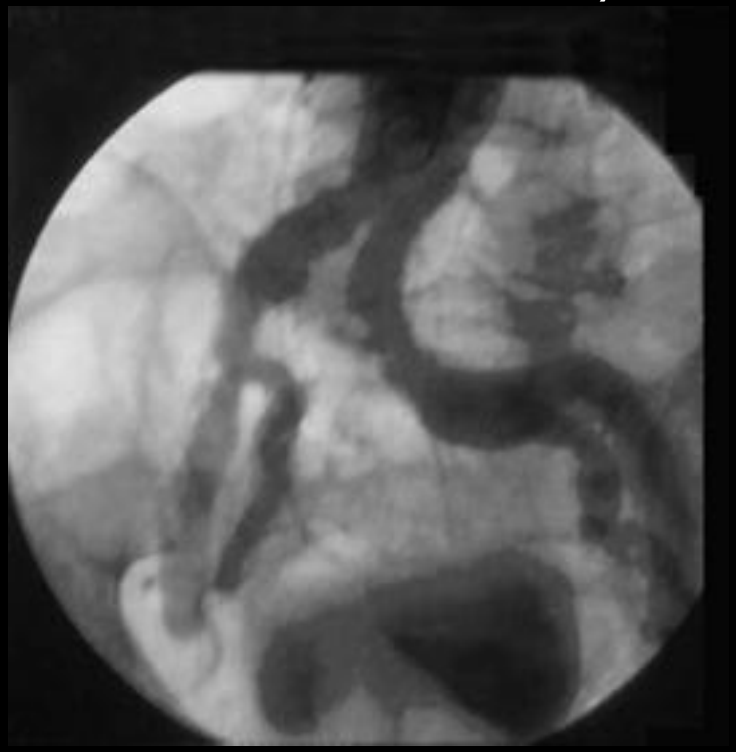

Artéria femoral E.18,5%

Stents mais utilizados

- Diâmetro 2,8cm
- Comprimento 9,0cm

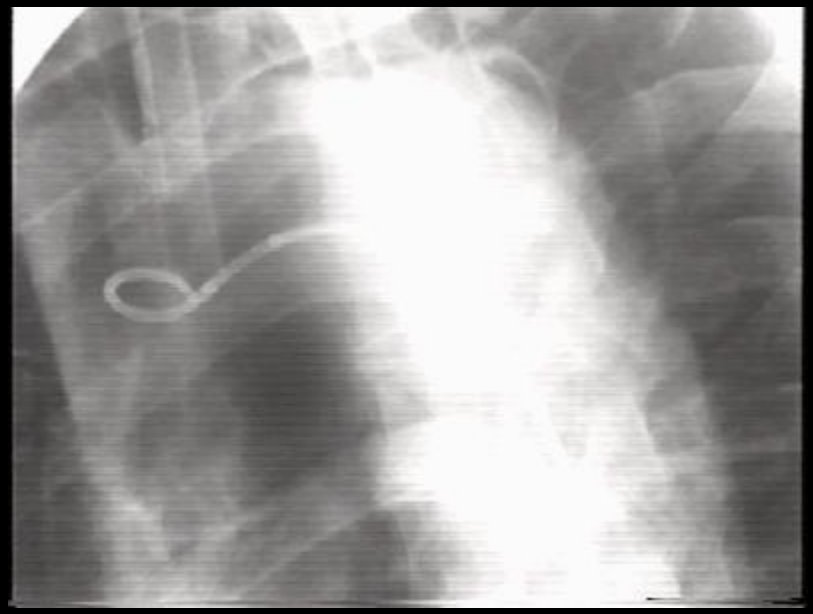

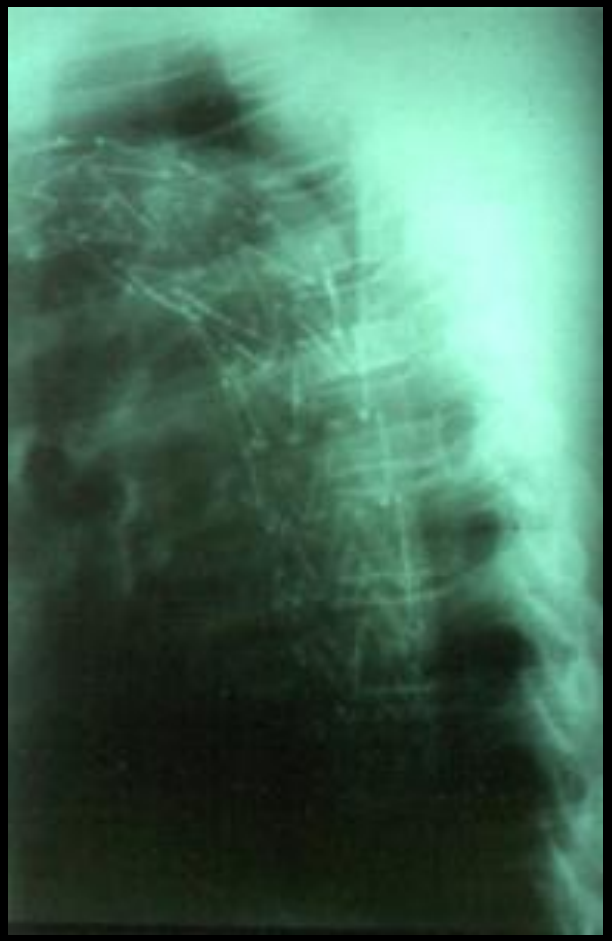

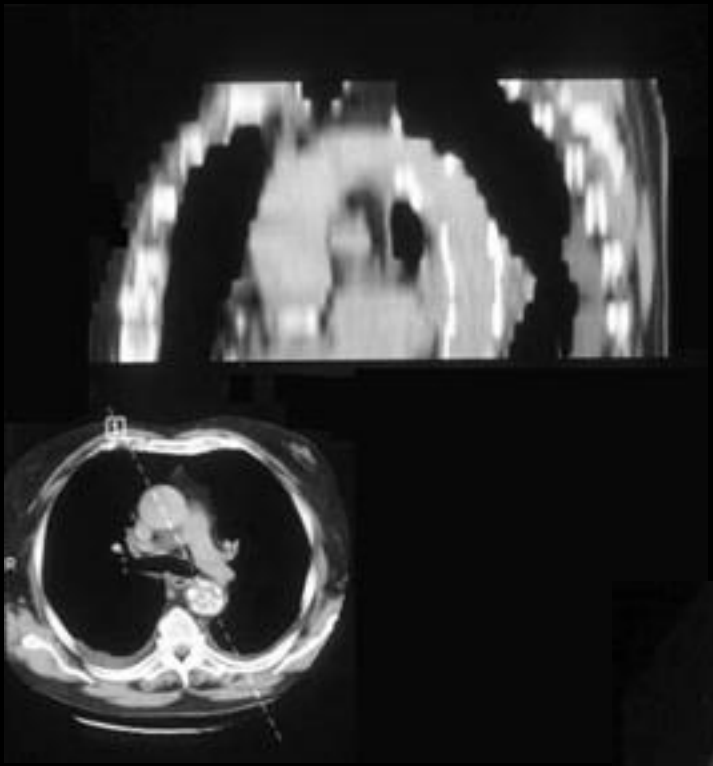

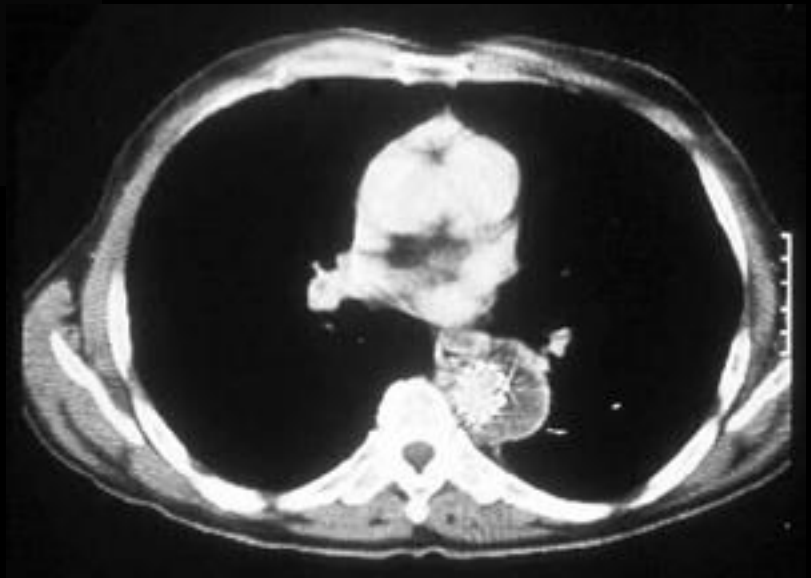

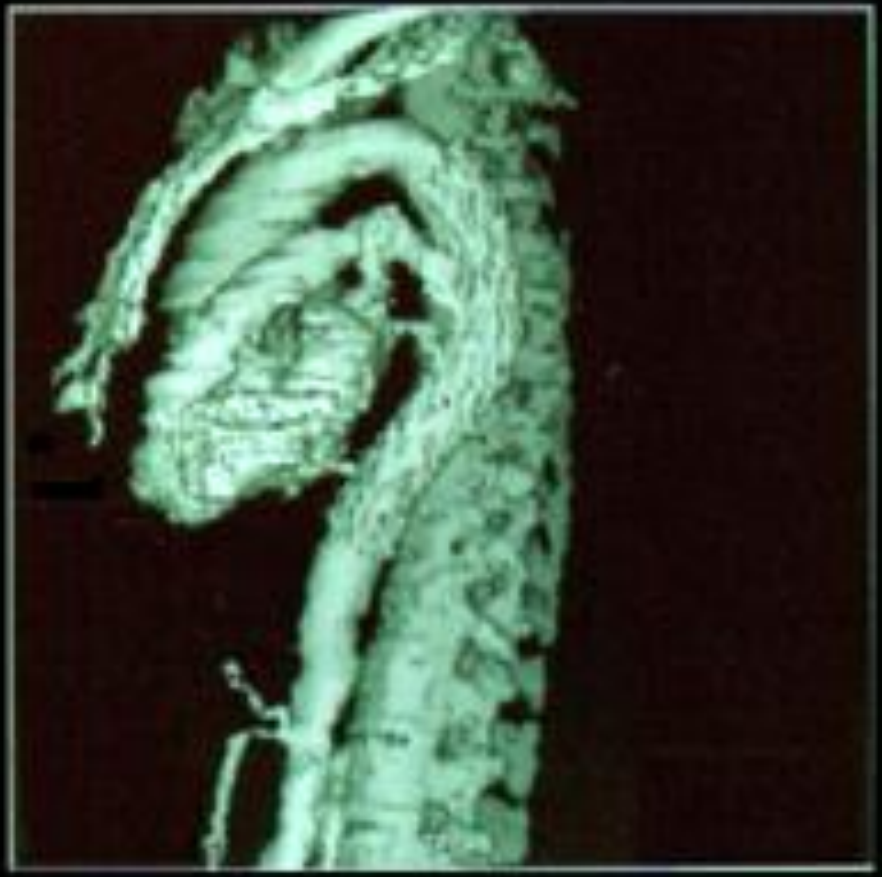

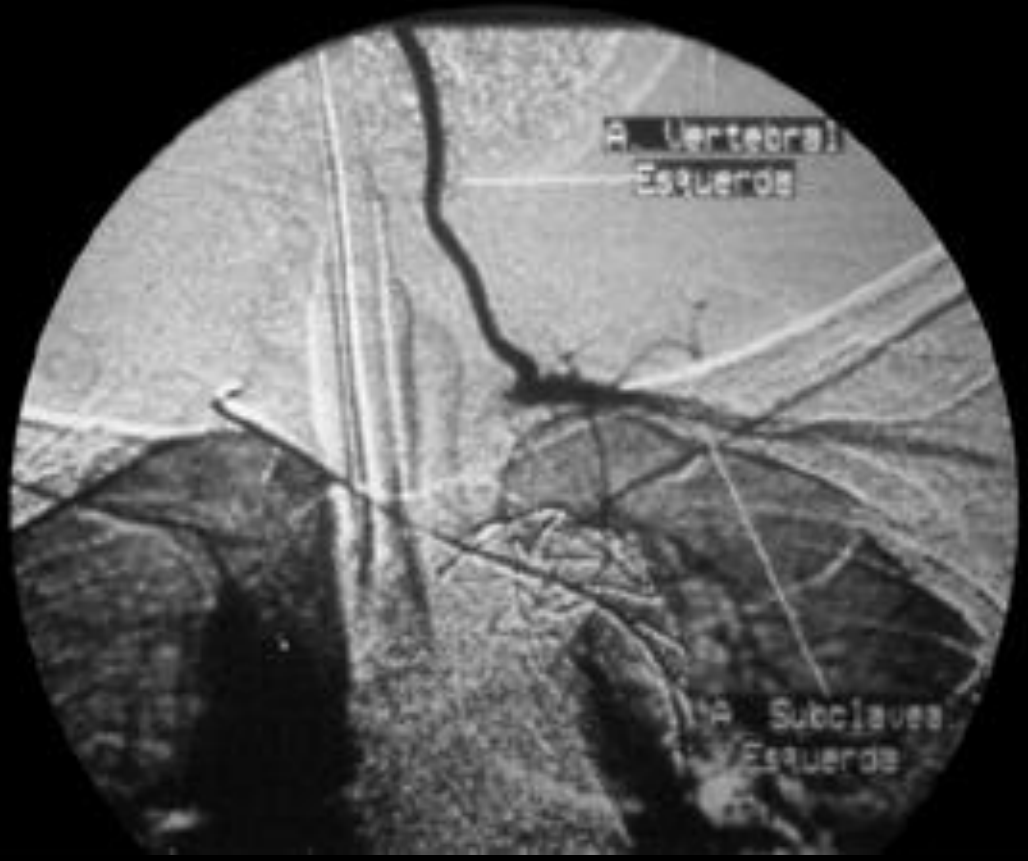
A. Vertebral
Esquerda
A. Subclavea
Esquerda

Complicações pós-operatórias

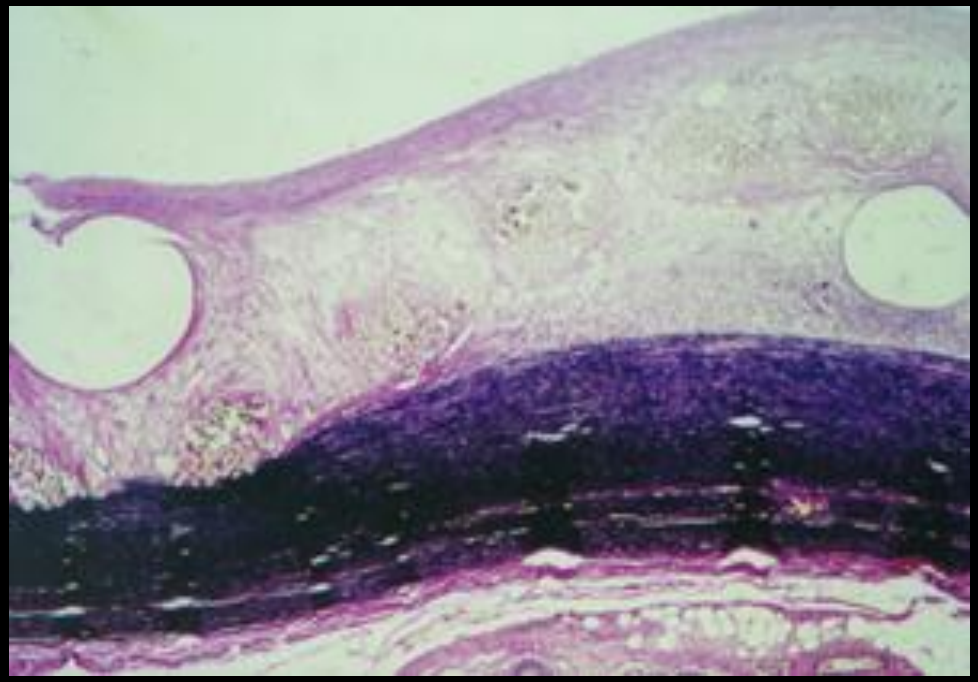

- Febre 22,2%
- Vazamentos 7,4%
- Insuficiência Renal 7,4%
- Isquemia M.I. 7,4%
- Infecção cateter diálise 3,7%

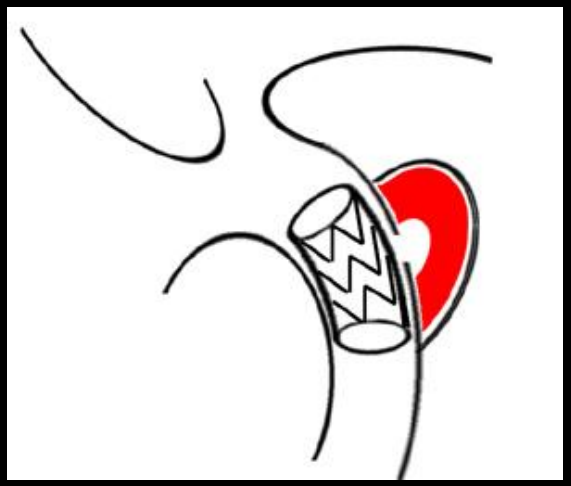

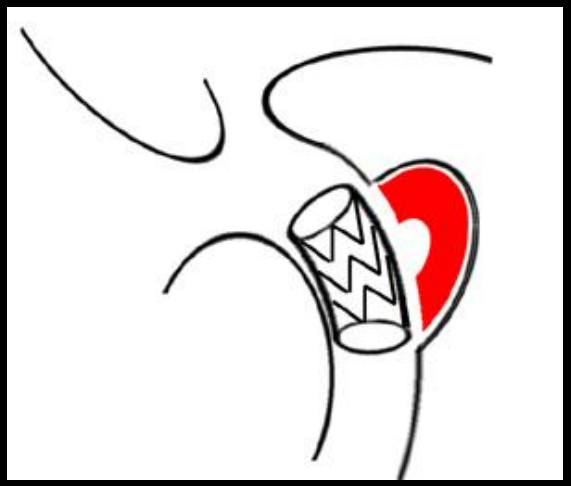

Mortalidade - 2,9%

- Precoce - 1 paciente

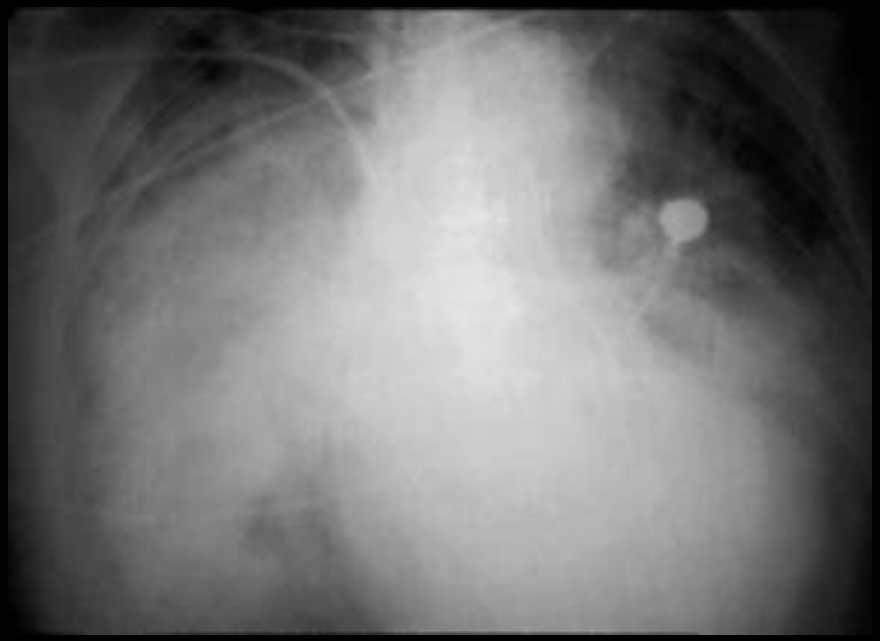

- Tardia - 2 pacientes

Curva atuarial de sobrevivência

Curva atuarial de pacientes livres de eventos não fatais

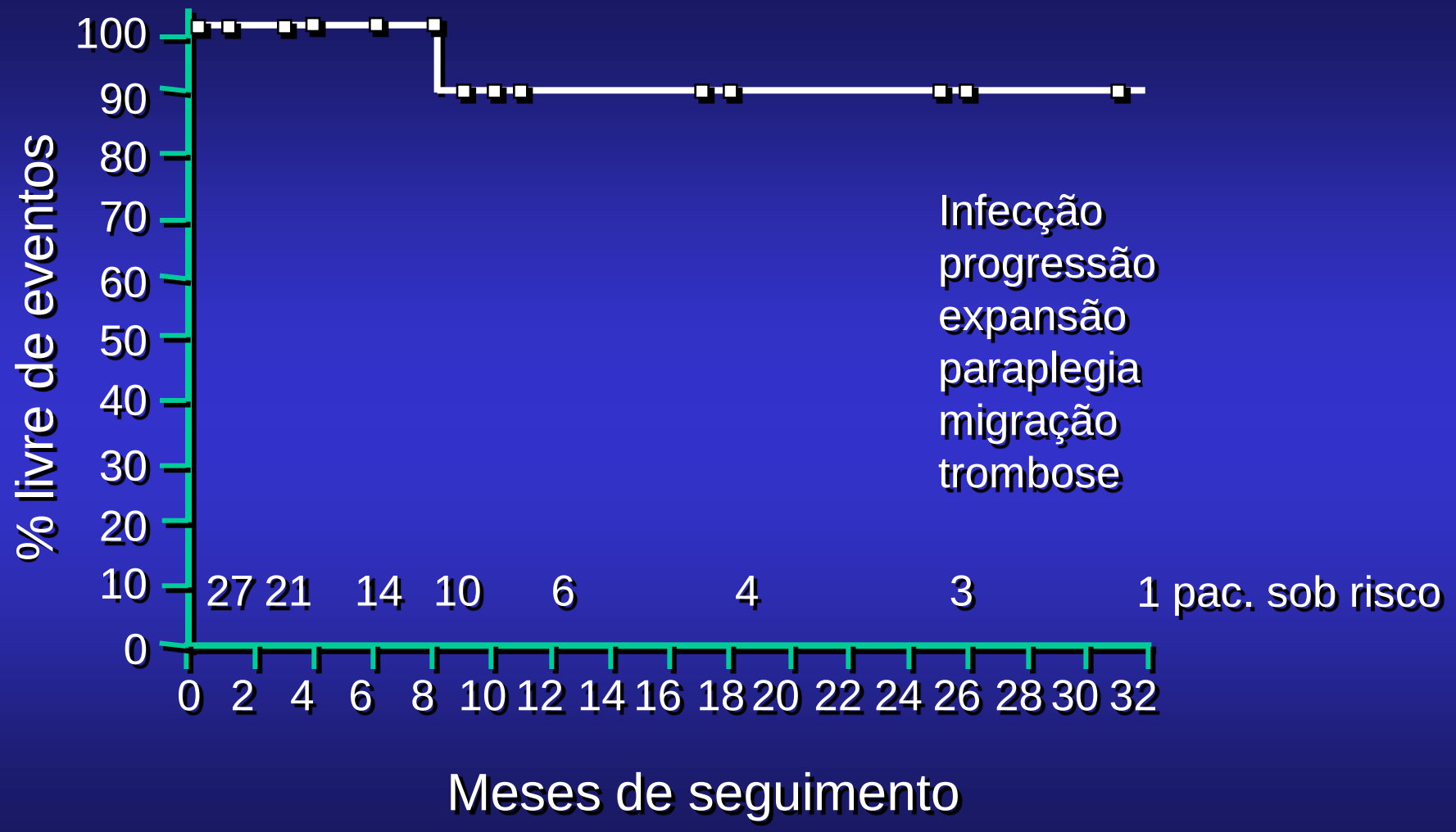

Conclusões

1- Esta nova técnica é uma alternativa promissora no tratamento dos pacientes com dissecção da aorta descendente, devido à sua simplicidade, assim como à baixa mortalidade associada.

2 - o procedimento determinou a trombose da falsa luz, a curto prazo, todavia ressaltamos a necessidade de estudos prospectivos e a longo prazo para observação do comportamento dos *Stents* aórticos.